

CLINICAL INVESTIGATION

Prostate

INTRAOPERATIVE RADIOTHERAPY DURING RADICAL PROSTATECTOMY FOR LOCALLY ADVANCED PROSTATE CANCER: TECHNICAL AND DOSIMETRIC ASPECTS

MARCO KRENGLI, M.D.,* CARLO TERRONE, M.D.,† ANDREA BALLARÈ, M.D.,* GIANFRANCO LOI, PH.D.,‡
ROBERTO TARABUZZI, M.D.,† GIAN SILVIO MARCHIORO, M.D.,† DEBORA BELDÌ, M.D.,*
ELEONORA MONES, PH.D.,‡ CESARE BOLCHINI, R.T.,* ALESSANDRO VOLPE, M.D.,† AND BRUNO FREA, M.D.‡

Departments of *Radiotherapy, †Urology, ‡Medical Physics, University Hospital Maggiore della Carità, Novara, Italy; and §Department of Urology, Hospital S. Maria della Misericordia, Udine, Italy

Purpose: To analyze the feasibility of intraoperative radiotherapy (IORT) in patients with high-risk prostate cancer and candidates for radical prostatectomy.

Methods and Materials: A total of 38 patients with locally advanced prostate cancer were enrolled. No patients had evidence of lymph node or distant metastases, probability of organ-confined disease >25%, or risk of lymph node involvement >15% according to the Memorial Sloan-Kettering Cancer Center Nomogram. The IORT was delivered after exposure of the prostate by a dedicated linear accelerator with beveled collimators using electrons of 9 to 12 MeV to a total dose of 10–12 Gy. Rectal dose was measured in vivo by radiochromic films placed on a rectal probe. Administration of IORT was followed by completion of radical prostatectomy and regional lymph node dissection. All cases with extracapsular extension and/or positive margins were scheduled for postoperative radiotherapy. Patients with pT3 to pT4 disease or positive nodes received adjuvant hormonal therapy.

Results: Mean dose detected by radiochromic films was 3.9 Gy (range, 0.4–8.9 Gy) to the anterior rectal wall. The IORT procedure lasted 31 min on average (range, 15–45 min). No major intra- or postoperative complications occurred. Minor complications were observed in 10/33 (30%) of cases. Of the 27/31 patients who completed the postoperative external beam radiotherapy, 3/27 experienced Grade 2 rectal toxicity and 1/27 experienced Grade 2 urinary toxicity.

Conclusions: Use of IORT during radical prostatectomy is feasible and allows safe delivery of postoperative external beam radiotherapy to the tumor bed without relevant acute rectal toxicity. © 2010 Elsevier Inc.

Intraoperative radiotherapy, Radical prostatectomy, Prostate cancer, Rectal dosimetry, Acute toxicity.

INTRODUCTION

Radical prostatectomy or definitive radiotherapy are the commonly accepted standard treatments for localized prostate cancer achieving high rates of biochemical control. In contrast, no treatment modality alone is able to achieve a satisfactory rate of disease control in case of locally advanced/high risk disease. Therefore, combination treatment including surgery, radiotherapy, and hormonal therapy may be used to optimize the clinical results (1, 2). Identification of patients at high risk for local failure may be obtained by using parameters such as high preoperative PSA, Gleason score ≥ 7 , clinical stage $\geq T2c$, and at least two thirds positive biopsy cores (3, 4).

As far as radiation treatment is concerned, recent studies have found a low alpha/beta ratio in prostate cancer (5), suggesting that the administration of high doses per fraction may represent a potential advantage for local control. However, studies using

nonconventional dose/fractionation schedules should carefully take into consideration the effects on the organs at risk.

Intraoperative radiotherapy (IORT) has been used for several tumor locations as a boost or as sole radiation treatment after or before tumor resection to improve local tumor control (6). To date, very few studies on the use of IORT for prostate cancer have been published using different technical approaches and showing promising preliminary results (7–10).

The purpose of the present study is to analyze the feasibility of IORT and to describe the technical and dosimetric aspects in patients with high-risk prostate cancer and candidates for radical prostatectomy.

METHODS AND MATERIALS

Between September 2005 and October 2008, 38 patients with locally advanced prostate cancer were included in the present study.

Reprint requests to: Marco Krengli, M.D., Radiotherapy, University of “Piemonte Orientale,” Via Solaroli 17, 28100 Novara, Italy. Tel: +39-0321-3733424; Fax: +39-0321-3733698; E-mail: krengli@med.unipmn.it

Conflict of interest: none.
Received Jan 12, 2009, and in revised form Feb 26, 2009.
Accepted for publication March 5, 2009.

Informed consent was obtained according to the rules of our Institution. Inclusion criteria were: Gleason score ≥ 7 , clinical stage $\geq T2c$, or PSA >10 ng/ml. Patients with evidence of lymph node or distant metastases, probability of organ-confined disease $>25\%$, and risk of lymph node involvement $>15\%$ according to the Memorial Sloan Kettering Cancer Center Nomogram (11) were excluded. Age >76 years and diagnosis of inflammatory bowel disease were other exclusion criteria. The main patient's characteristics are listed in Table 1.

All cases were preliminary discussed in a multidisciplinary meeting with radiation oncologists, urologists, anaesthesiologists, physicists, and radiation technologists to define the clinical and technical aspects of the IORT procedure.

After induction of general anaesthesia and before starting the surgical procedure, a rectal probe (12 cm in length and 2.5 cm in diameter) was applied for dosimetry (Fig. 1). The IORT procedure started after exposure of the anterior aspect of the prostate, section of the pubo-prostatic ligaments, and control of the deep dorsal vein plexus. First, the anterior–posterior prostate diameter and the distance from prostate surface to the anterior rectal wall was measured by intraoperative ultrasound (US). Based on clinical and US parameters, the appropriate collimator and beam energy were chosen to include the prostate gland and the surrounding soft tissues with a suitable margin for subclinical disease of 0.5 to 1 cm.

The IORT was delivered by a dedicated linear accelerator (Mobetron, Intraop, Sunnyvale, CA) using an electron beam of 9 to 12 MeV to a total dose of 10 Gy in the first 3 patients and of 12 Gy in the following patients. The dose was prescribed at the 90% isodose. In all patients, rectal dose was measured *in vivo* by four radiochromic films placed on the surface of the rectal probe to detect the dose at the level of the anterior, posterior, and laterals rectal walls.

Use of IORT was followed by radical prostatectomy and regional lymph node dissection. All patients with evidence at pathology examination of extracapsular extension and/or positive surgical margins were scheduled for postoperative radiotherapy. Adjuvant hormonal therapy was administered in patients with pT3 to pT4 disease or positive nodes. Indication for postoperative radiotherapy and adjuvant hormonal therapy followed our institutional protocol, based on the current literature that confirms long-term success rates for high-risk patients with a multimodality treatment approach (2, 12). Postoperative external beam radiotherapy was delivered to prostate bed about 3 months after surgery by using three-dimensional conformal radiotherapy with four to six customized beams or dynamic arcs to a total dose of 46 to 50 Gy in 25 fractions (2 Gy/fraction).

Table 1. Preoperative characteristics of study patients

No. of patients	38
Age, y, median (range)	67 (56–76)
Karnofsky performance status, mean	90
Initial PSA (ng/ml), median (range)	39.5 (2.9–63.9)
Biopsy Gleason score	
<7	5 (15%)
≥ 7	33 (85%)
Clinical stage* (TNM 2002 classification)	
$\leq T2c$	11 (29%)
$>T2c$	27 (71%)
Neoadjuvant hormone therapy	11 (29%)

* Based on digital rectal examination, transrectal ultrasound, and abdominal computed tomography.




Fig. 1. Rectal probe for *in vivo* dosimetry with four radiochromic films on the surface to detect dose at the level of the anterior, posterior, and laterals rectal walls.

RESULTS

The target volume was irradiated by using beveled collimators with 15° to 30° angles (median 30°) and internal diameter ranging from 4.5 cm to 6.5 cm (median 5.5 cm) (Table 2).

The mean prostate anterior–posterior diameter was 3.3 cm (range, 2.2–5.7 cm). The mean depth of the anterior rectal wall was 3.6 cm (range, 2.6–6.2 cm). The mean doses detected by the radiochromic films were 3.9 Gy to the anterior rectal wall, 1.1 Gy, and 1.4 Gy to the left and right rectal walls respectively and 0.1 Gy to the posterior rectal wall. In particular, the dose measured at the level of the anterior rectal wall ranged from 0.4 Gy to 8.9 Gy (Fig. 2).

Mean overall treatment time (radical prostatectomy + IORT) was 236 min. The IORT procedure lasted on average 31 min (range, 15–45 min), and the duration decreased over time with increasing experience. No major perioperative complications occurred. The percentage of patients requiring transfusion was 86% (33/38 patients). Minor complications were observed in 10/33 (30%) of patients and included five lymphoceles (16%) and two pelvic hematomas (6%). Four lymphoceles were treated by percutaneous drainage because of worsening abdominal pain and distension, and 1 patient required a surgical laparoscopic repair.

No patient experienced symptoms of acute rectal toxicity in relation to IORT procedure.

In the 27/31 patients who completed the postoperative external beam radiotherapy, 3/27 patients experienced Grade 2 rectal and 1/27 patients Grade 2 urinary toxicity according to the Radiation Therapy Oncology Group (RTOG) scale (13) (Table 3). A total of 25 patients received adjuvant hormonal therapy.

Pathology data and margins status are reported in Table 4. Mean follow-up was 18.2 months (range, 3–36 months). Median PSA 1 month after the procedure was 0.05 ng/ml (range, 0.003–5.1 ng/ml).

DISCUSSION

The rationale of IORT during radical prostatectomy is based on the unsatisfactory results obtained by conventional

Table 2. Technical features of intraoperative radiotherapy (IORT) procedure

IORT procedure	No (%) of patients
Collimator size (cm)	
4.5	1 (2.6%)
5.0	12 (31.6%)
5.5	15 (39.5%)
6.0	7 (18.4%)
6.5	2 (5.3%)
7.0	1 (2.6%)
Bevel angle	
15°	1 (2.6%)
30°	37 (97.4%)
Energy (MeV)	
9	9 (23.7%)
12	29 (76.3%)
Total dose (Gy)	
10	3 (7.9%)
12	35 (92.1%)

treatments in patients with intermediate–high-risk prostate cancer. Patients with T3 stage treated by multimodality approach including radical prostatectomy have a 10-year relapse-free survival rate even lower than 45% and a local failure rate higher than 40% (4, 14). Our study focused on patients with at least one of the following risk factors: Gleason score ≥ 7 , T clinical stage $\geq 2c$, or PSA >10 ng/ml. This population represents a subset of patients at relatively high risk for biochemical failure and local recurrence who are usually treated by surgery and/or radiotherapy frequently associated with hormonal therapy (12, 15–17).

The percentage of positive surgical margins in our series (71%) was relatively higher compared with that reported by Orecchia *et al.* (9) and Saracino *et al.* (10), who observed respectively 55% and 41% positive or close margins after surgical resection. This may be explained by the slightly different patient population enrolled in these studies. In fact, 71% of cases were classified as cT3 in our series, whereas only 55% and 41% of cases had this clinical stage in the series by Orecchia *et al.* and Saracino *et al.* respectively (9, 10). The use of the present approach may help us to find out if the addition of IORT to external beam radiotherapy will allow compensation for such relatively high rate of microscopical residual disease.

As far as the technical aspects are concerned, we chose to deliver IORT before prostate removal according to what was done by Orecchia *et al.* (9), but in contrast to what was proposed by Saracino *et al.* (10) who performed the IORT procedure on the urethral anastomosis just after radical prostatectomy. A potential advantage of our approach is the optimization of the ir-

Table 3. Acute toxicity after postoperative external beam radiotherapy according to the Radiation Therapy Oncology Group scale (13)

Toxicity	G0 patients, n (%)	G1 patients, n (%)	G2 patients, n (%)
Gastrointestinal toxicity	22/27 (81.5%)	2/27 (7.5%)	3/27 (11%)
Genitourinary toxicity	25/27 (93%)	1/27 (3.5%)	1/27 (3.5%)

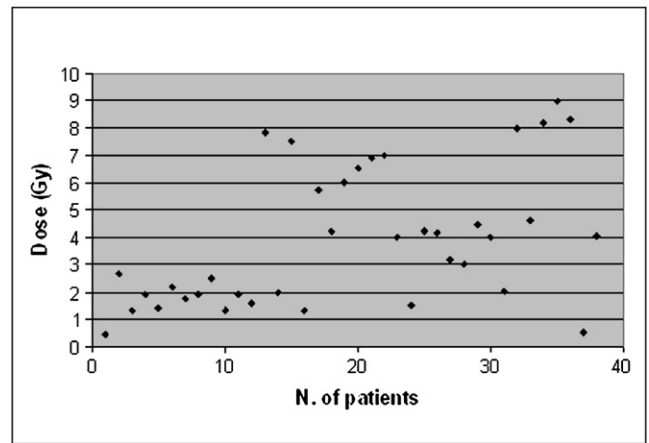


Fig. 2. Maximum rectal dose measured *in vivo* by radiochromic films placed on the surface of a rectal probe.

radiated volume including prostate and surrounding tissues possibly infiltrated by tumor cells. Using our technique, the dose to the rectum can be limited because of the dose absorbed by the prostate tissue. Finally, our approach can potentially achieve a better irradiation of the prostatic apex that is frequently site of recurrence. Conversely, a potential risk of the approach proposed by Saracino *et al.* (10) is the increase of long-term complications such as strictures of the vesico-urethral anastomosis or rectal damage because of the direct irradiation of the anterior rectal wall.

To optimize the IORT procedure, a close cooperation with the surgeon is essential. The urologist has to expose the prostate and place a stitch on the bladder neck to facilitate the definition of the target while positioning the collimator. Another crucial aspect is the choice of the most appropriate diameter, bevel angle, and beam energy to deliver an adequate dose to the prostate (*i.e.*, the tumor) while sparing the underlying rectal wall. For this purpose, we performed a US measure of the prostate with special attention to the anterior–posterior diameter and to the distance between the prostate surface and the anterior rectal wall.

An advantage of the Mobetron machine used at our center is the so-called “soft-docking.” In other terms, the collimator is not directly connected with the nozzle but is positioned by

Table 4. Pathological staging according to the 2002 TNM classification and surgical margins status

No. of patients	38
p Gleason Score	
<7	2 (5%)
≥ 7	36 (95%)
Pathological stage *	
$\leq T2c$	14 (37%)
>T2c	24 (63%)
pN0	31 (82%)
pN1	7 (18%)
Positive surgical margins	27 (71%)
– focal	14 (51.8%)
– diffuse	13 (48.2%)
Negative surgical margins	11 (29%)

* According to the TNM 2002 classification.

the operator and fixed to the operating table. During the IORT procedure, an air gap is maintained between the collimator and the nozzle. This optimizes the pressure on the prostate and helps in displacing the bladder outside the treatment field, avoiding the risk of traumatizing the tissues with movements of the machine.

Based on the intraoperative anatomical findings and the US measurements, we generally chose 30° collimators 5 to 6 cm in diameter and an energy level of the beam between 9 and 12 MeV energy to optimize the coverage of the prostate gland.

Rectal dosimetry was performed in all patients and showed a mean dose at the level of the anterior rectal wall of 3.9 Gy (range, 0.4–8.9 Gy). A relevant dose reduction was constantly observed at the level of the posterior rectal wall, meaning that the rectum was in the steep component of the in depth dose–distribution curve. The variation of the dose detected by rectal dosimetry in the anterior rectal wall in the different patients may be explained by a number of factors: the different prostate diameters requiring different beam energy, the different bevel angle of the collimator positioned on the prostate surface, and the two levels of prescribed dose that in the beginning of the study was 10 Gy and subsequently increased to 12 Gy. Our findings are consistent with those reported by Orecchia *et al.* (9), in a series of 11 patients treated with 10-MeV beam energy before prostate removal, who found a mean rectal dose of 3.3 Gy with a range of 2.5 to 4.4 Gy; these values are different from those of Saracino *et al.* and Soriani *et al.* (10, 18) who reported a rectal dose lower than 1% of the prescription dose in their series undergoing irradiation after prostatectomy with a different technique. This measured low rectal dose may be related to the fact that in these series the collimator was

placed near the prostate apex so that the isodose curves included only the very lower aspect of the rectum. No data about rectal dosimetry are reported in the articles from Japan (7, 8, 19).

As far as surgical procedure, the percentage of patients requiring blood transfusion was higher compared with laparoscopic surgery but comparable to other experiences of open surgery for locally advanced disease (20–22). We have to take into account that the blood loss may be higher with this approach because, during intraoperative irradiation, the hemostatic control is not possible. Finally, the incidence of perioperative complications after IORT was low and was similar to that reported for radical prostatectomy alone in the treatment of locally advanced prostate cancer (21). This is probably due to the relatively short additional time required for intraoperative irradiation compared to the overall time of a typical radical prostatectomy and to the moderate dose of radiation to the rectum as verified by *in vivo* dosimetry.

CONCLUSION

In conclusion, IORT during radical prostatectomy is feasible. The technical approach described in the present article allowed safe delivery of 12 Gy to the prostate and the surrounding tissues and a further 46–50 Gy by postoperative radiotherapy to the tumor bed without relevant acute rectal toxicity. In terms of rectal dosimetry, the maximum dose measured at the level of the anterior rectal wall ranged from 0.4 Gy to 8.9 Gy, with a mean value of 3.9 Gy. No major postoperative complications were observed in our series. Longer follow-up time is needed to assess the results in regard to long-term side effects and biochemical control.

REFERENCES

- Bolla M, Collette L, Blank L, *et al.* Long-term results with immediate androgen suppression and external irradiation in patients with locally advanced prostate cancer (an EORTC study): A phase III randomised trial. *Lancet* 2002;360:103–106.
- Van Poppel H. An analysis of radical prostatectomy in advanced stage and high-grade prostate cancer. *Eur Urol* 2008;53:253–259.
- Porter CR, Kodama K, Gibbons RP, *et al.* 25-year prostate cancer control and survival outcomes: A 40-year radical prostatectomy single institution series. Clinical significance and therapeutic implications. *J Urol* 2006;176:569–574.
- Roehl KA, Han M, Ramos CG, Antenor JA, Catalona WJ. Cancer progression and survival rates following anatomical radical retropubic prostatectomy in 3,478 consecutive patients: Long-term results. *J Urol* 2004;172:910–914.
- Fowler JF. The radiobiology of prostate cancer including new aspects of fractionated radiotherapy. *Acta Oncol* 2005;44:265–276.
- Willett CG, Czito BG, Tyler DS. Intraoperative radiation therapy. *J Clin Oncol* 2007;25:971–977.
- Kojima S, Satake I, Tujii T, Tari K, Sakura M. Intraoperative radiotherapy (IORT) in prostatic cancer. *Hinyokika Kyo* 1988;34:1397–1402.
- Higashi Y, Hyochi N, Tari K. Intraoperative radiotherapy combined with external beam radiation for prostate cancer without metastasis. *Nippon Rinsho* 1998;56:2177–2180.
- Orecchia R, Jereczek-Fossa BA, Ciocca M, *et al.* Intraoperative radiotherapy for locally advanced prostate cancer: Treatment technique and ultrasound-based analysis of dose distribution. *Anticancer Res* 2007;27:3471–3476.
- Saracino B, Gallucci M, De Carli P, *et al.* G. Phase I–II study of intraoperative radiation therapy (IORT) after radical prostatectomy for prostate cancer. *Int J Radiat Oncol Biol Phys* 2008;71:1049–1056.
- Fearn P, Kattan MW. Prostate nomograms. Available at: <http://www.mskcc.org/mskcc/html/10088.cfm>. Accessed May 7, 2007.
- Ozen H, Yazici S, Kubilay I. Management of high-risk localized prostate cancer. *Eur Urol* 2009;8(Suppl):439–447.
- Cox JD, Stetz J, Pajak TF. Toxicity criteria of the Radiation Therapy Oncology Group (RTOG) and the European Organization for Research and Treatment of Cancer (EORTC). *Int J Radiat Oncol Biol Phys* 1995;31:1341–1346.
- Carver BS, Bianco FJ, Scardino PT, Eastham JA. Long-term outcome following radical prostatectomy in men with clinical stage T3 prostate cancer. *J Urol* 2006;176:564–568.
- Bolla M, van Poppel H, Collette L, *et al.* Postoperative radiotherapy after radical prostatectomy: A randomised controlled trial (EORTC trial 22911). *Lancet* 2005;366:572–578.
- Messing EM, Manola J, Yao J, *et al.* Immediate versus deferred androgen deprivation treatment in patients with node-positive prostate cancer after radical prostatectomy and pelvic lymphadenectomy. *Lancet Oncol* 2006;7:472–479.

17. Brant AI, Judson DD, Laureano JR, *et al.* Long-term outcomes of radical prostatectomy with multimodal adjuvant therapy in men with a preoperative serum prostate-specific antigen level ≥ 50 ng/ml. *Cancer* 2008;113:1544–1551.
18. Soriani A, Landoni V, Marzi S, *et al.* Setup verification and in vivo dosimetry during intraoperative radiation therapy (IORT) for prostate cancer. *Med Phys* 2007;34:3205–3210.
19. Takahashi M, Okada K, Shibamoto Y, *et al.* Intraoperative radiotherapy in the definitive treatment of localized carcinoma of the prostate. *Int J Radiat Oncol Biol Phys* 1985;11:147–151.
20. Lerner SE, Blute ML, Zincke H. Extended experience with radical prostatectomy for clinical stage T3 prostate cancer: Outcome and contemporary morbidity. *J Urol* 1995;154:1447–1452.
21. Gontero P, Marchioro G, Pisani R, *et al.* Is radical prostatectomy feasible in all cases of locally advanced non-bone metastatic prostate cancer? Results of a single-institution study. *Eur Urol* 2007;51:922–929.
22. Konety BR, Eastham JA, Reuter VE, *et al.* Feasibility of radical prostatectomy after neoadjuvant chemohormonal therapy for patients with high risk or locally advanced prostate cancer: Results of a phase I/II study. *J Urol* 2004;171:709–713.