

The American Journal of Surgery 195 (2008) 405–409  
The Midwest Surgical Association

## Clinical results of intraoperative radiation therapy for patients with locally recurrent and advanced tumors having colorectal involvement

Christina P. Williams, M.D.<sup>a</sup>, Harry L. Reynolds, M.D.<sup>a,\*</sup>, Conor P. Delaney, M.D., Ph.D.<sup>a</sup>,  
Brad Champagne, M.D.<sup>a</sup>, Vincent Obias, M.D.<sup>a</sup>, Yong-Geul Joh, M.D.<sup>a</sup>, Jim Merlino, M.D.<sup>b</sup>,  
Timothy J. Kinsella, M.D.<sup>c</sup>

<sup>a</sup>Department of Surgery, Case Western Reserve University, University Hospitals, Case Medical Center, Cleveland, OH, USA

<sup>b</sup>Department of Surgery, Case Western Reserve University School of Medicine, Metro Health Medical Center, Cleveland, OH, USA

<sup>c</sup>Radiation Oncology Department, Case Western Reserve University, University Hospitals, Case Medical Center, Cleveland, OH, USA

Manuscript received December 4, 2007; revised manuscript December 4, 2007

### Abstract

**Background:** Intraoperative radiation therapy (IORT) may be useful in the treatment of patients who have a locally advanced primary and recurrent abdominopelvic neoplasm with colorectal involvement.

**Methods:** A retrospective review of colorectal cancer patients treated since 1999 with IORT using the Mobetron device.

**Results:** Forty patients underwent colectomy or proctectomy with IORT. All patients had evidence of local extension to contiguous structures and based on preoperative staging were deemed by the operating surgeon as being likely to have incomplete resection. IORT was selected as an alternative to sacrectomy or exenteration for an expected close margin in 10 patients. Mean survival was  $35 \pm 26$  months, and 1 patient had local recurrence.

**Conclusions:** The introduction of IORT has allowed a selective treatment approach to locally advanced primary and recurrent neoplasms, which traditionally would have been deemed unresectable. Using IORT, extended resections may be avoided in selected high-risk patients with low risk of local recurrence and minimal morbidity. © 2008 Elsevier Inc. All rights reserved.

**Keywords:** Colorectal cancer; Radiation; Intraoperative; Recurrence; Sacrectomy

Surgery remains the primary management modality for patients with early-stage colorectal cancer. Neoadjuvant chemotherapy and radiation have become the standard of care for patients with stages II and III rectal cancer. Patients who present with locally advanced primary or recurrent colon and rectal cancers, particularly those with adjacent organ, pelvic sidewall, or sacral involvement, present a significant management dilemma. Although surgery plays a pivotal role in the treatment of these patients, a multimodality team approach is necessary to optimize outcomes.

Preoperative chemotherapy and radiation therapy is frequently appropriate in these patients in an attempt to min-

imize tumor burden before what will often be a challenging pelvic dissection. Surgical decision making regarding the extent of resection presents another clinical dilemma. In the reoperated abdomen and pelvis, standard planes do not exist, and it can be impossible to differentiate clinically scarring, radiation change, and tumor. Frozen-section evaluation of margins is difficult and often unhelpful, secondary to the large surface area, which must be evaluated. With expected microscopic or gross involvement, resection of the adjacent organs, the pelvic sidewall, or the sacrum is preferable but not always feasible. In the patient who is medically unfit, or who has unresectable disease at a margin, several studies have shown that intraoperative radiation therapy (IORT) is a useful adjunct and may provide a satisfactory means of local control and potential cure with acceptable morbidity [1–7]. This article outlines a single institution's experience with IORT using a mobile electron-beam radiation device (Mobetron) as an adjunct to surgical resection.

\* Corresponding author. Tel.: +1-216-844-5798; fax: +1-216-844-5957.  
E-mail address: harry.reynolds@uhhospitals.org

Table 1  
Cancer stage at time of surgery, margins and survival for all patients and divided by type of cancer

	Primary rectal	Recurrent rectal	Primary colon	Recurrent colon	Appendiceal cancer	Other cancer
n	14	12	2	6	2	4
STAGE 4	6	4	1	2	0	1
STAGE 3	4	3	1	2	0	3
STAGE 2	3	5	0	1	2	0
STAGE 1	1	0	0	1	0	0
# with positive margins	4 (29%)	5 (42%)	0	1 (17%)	0	2 (50%)
# with fibrosis or treated cancer at margins	2 (14%)	3 (25%)	0	2 (33%)	0	0
# with abnormal margins	6 (43%)	8 (67%)	0	3 (50%)	0	2 (50%)
median survival months (range)	22 (0–86)	27 (6–92)	30 (18–41)	56 (22–85)	27 (15–39)	18 (7–38)
mean survival months (STD)	33 ( $\pm$ 26)	36 ( $\pm$ 30)	30 ( $\pm$ 16)	55 ( $\pm$ 21)	27 ( $\pm$ 17)	20 ( $\pm$ 15)
# with local recurrence	0	1 (8%)	0	0	0	0
# with metastatic recurrence	7 (50%)	5 (42%)	2 (100%)	2 (33%)	0	0
# Surviving To Date	6 (43%)	7 (48%)	2 (100%)	5 (83%)	2 (100%)	4 (100%)

STD = standard deviation.

## Methods

A retrospective review ( $n = 40$ ) of a prospectively maintained database of patients undergoing IORT and surgery for colon and rectal malignancies between 1999 and 2006 was performed. Patients  $\geq 18$  years who had either a primary or secondary malignancy with colonic or rectal involvement treated with IORT were included. Patients who had carcinomatosis, who had tumors deemed unresectable, or who did not undergo IORT despite presurgical plans were excluded. Records were evaluated to determine age, staging, margins, surgical procedure, chemotherapy and radiation, complications, local recurrence, and survival. Approval for this study was obtained from the Case Comprehensive Cancer Center Institutional Review Board.

## Results

Forty colorectal patients (22 men and 18 women) underwent IORT for carcinoma involving the colon or rectum using the Mobetron device, a portable unit that can be used without extensive shielding. A special operating room (OR) table was used in all patients to allow for proper position of the patient with the Mobetron unit. Age ranged from 40 to 86 years ( $65 \pm 12$ ). There were 26 patients with rectal cancer, including 12 with recurrences, and 8 patients with colon cancer, including 6 with recurrences. Two patients had advanced appendiceal or appendiceal base tumors. Four other patients had other lesions secondarily involving the colon or rectum, including 2 patients with recurrent ovarian cancer, 1 patient with recurrent endometrial cancer, and 1 patient with recurrent duodenal carcinoma. Half of the patients had recurrent tumors and had undergone at least 1 surgery before IORT; 28 had undergone previous chemotherapy; and 27 had undergone previous radiation therapy. Of these patients, 25 had received 5-FU along with their preoperative radiation. Two additional patients had concomitant 5-FU withheld because of toxicity.

Tumor stages are listed in Table 1 with pathologic staging after preoperative chemotherapy and radiation and presumed downstaging. All patients with rectal cancer had clinically advanced fixed and or tethered bulky pelvic lesions on examination, with imaging suggesting local inva-

sion. Likewise, colonic, appendiceal, and other lesions had bulky tumors, which appeared to have adjacent organ, abdominal wall, or pelvic sidewall involvement on presurgical imaging studies. As would be expected, there was a significant increase in survival associated with decreasing stage ( $P$  by log-rank test = .019 (Fig. 1).

All patients underwent the planned surgical resection, and in each case, there was concern over margins being close or involved secondary to advanced local disease and/or invasion of adjacent organs as seen on presurgical imaging. Fourteen patients underwent abdominal perineal resection; 10 underwent low anterior resection, 5 underwent low anterior resection with low Hartmann's; 5 underwent segmental colectomy; 2 underwent pelvic exenteration; 1 underwent colostomy; 1 underwent colectomy and duodenectomy; and 2 underwent local excision of recurrences. Twenty-six of the 40 patients (65%) underwent adjacent organ, abdominal wall, or pelvic sidewall excision.

In all patients, IORT was performed to the 90% isodose line. Decisions regarding dose as well as energy and size of

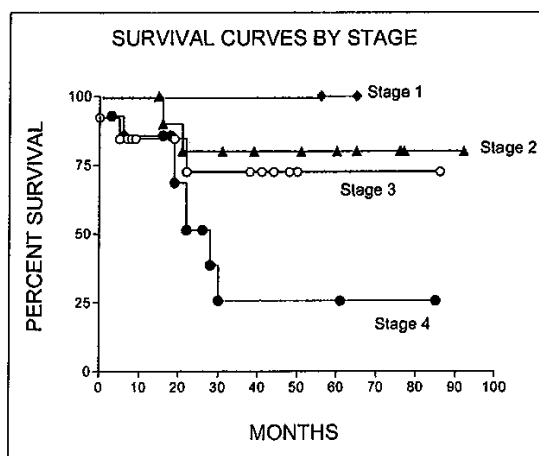


Fig. 1. Survival curves by stage after treatment for downstaging. Log-rank test for trend  $P = .112$ .

the cone used for radiation therapy were made by a radiation oncologist, who was present for the procedure. All doses were administered with the Mobetron device in a standard OR. Final margins were not available at the time of IORT. Cone size ranged from 3 to 12 cm in diameter (average  $6.4 \pm 1.8$  [SD]; median 6). The energy of the electron beam ranged from 6 to 12 MeV (average  $9.6 \pm 1.8$ ; median 9). These electron energies permitted tissue penetration of 4 to 5 cm. The total dose of radiation given ranged from 10 to 20 Gy (mean of  $11.8 \pm 2.2$ ; median 12). One patient had grossly positive margins at surgery, and despite being the only patient to receive a dose of 20 Gy, she experienced local recurrence and survived 22 months.

Of the 40 patients who received IORT, 48% (19 of 40) had positive margins ( $n = 12$ ) or evidence of treated cancer at the resection margin ( $n = 7$ ) (Table 1). There was no significant difference regarding crude survival in patients with microscopically positive margins, those with fibrosis or mucin at the margin, or those with negative margins ( $P = 0.41$ ; Fig. 2). There was a trend toward decreased survival in patients with positive margins. Survival was 29.5 and 58.4 months for patients with negative and fibrotic margins, respectively, compared with 19 months for patients with positive margins.

There were 14 deaths during the study period. Eight deaths were secondary to distant metastatic disease. Of the patients whose cause of death was not secondary to metastatic disease, 1 patient died from metastatic melanoma unrelated to treatment for rectal cancer; 1 died from multi-system organ failure after surgery; 1 died from secondary complications of a bowel obstruction, and 3 could not be contacted for follow-up; they were known to have died based on public social security number databases.

Median follow-up for our patients was 27 months. During this study period, 16 of 40 patients had metastatic recurrence of their disease. However, there was only 1 local recurrence in our 40 patients. The local recurrence occurred in the 1 patient in whom gross tumor was left behind and irradiated (Table 1).

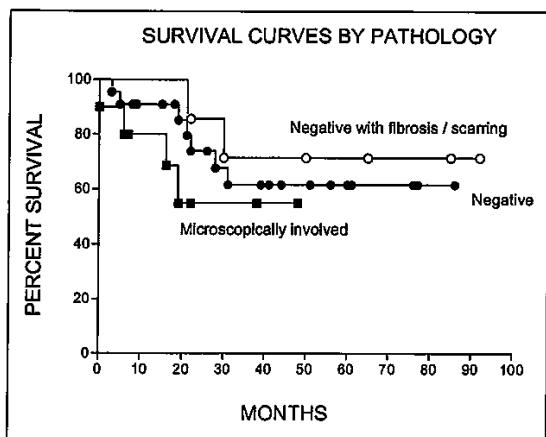


Fig. 2. Survival curves by margins on final pathology. Log-rank test for trend  $P = .41$ .

Table 2  
Complications after surgery with IORT

Early complications	No. of patients
Cardiac (eg, infarction, AF, CHF)	1
Deep vein thrombosis	1
Respiratory insufficiency	1
Abscess	4
Wound infection	4
UTI pyelonephritis	5
Bladder dysfunction	5
Urinary incontinence	2
Ileus	5
Diarrhea	1
Delirium tremens	1
Postoperative death	1
Late complications	
Ureteral stricture	3
Small-bowel obstruction	3
Pelvic/sacral pain	1
Leg pain/paresthesia	4
Pelvic fracture	4
Total no. of complications	46

AF = atrial fibrillation; CHF = congestive heart failure.

The most common complications involved the genitourinary system with bladder dysfunction and urinary tract infection, with ureteral stricture being the most frequent. The other common complications were ileus, wound infection, and leg pain or paresthesia (Table 2).

### Comments

To date, ours is the largest series of patients who underwent IORT for colorectal cancer using the Mobetron device. This system led to low rates of local recurrence and good overall survival in patients with locally advanced colorectal cancers. There was only 1 local recurrence during the study period. In 10 patients, IORT prevented the need for pelvic exenteration or sacrectomy and therefore avoided the associated morbidity of such. The low local recurrence rates can likely be attributed to the absence of gross tumor involvement of the margins in all but 1 patient. Because of relatively short follow-up, additional recurrences may occur in the future.

Low local recurrence rates were achieved with an acceptable incidence of postsurgical complications. Urinary retention rates after rectal surgery range from 10% to 30% compared with the 13% found by this study. The rate of urinary tract infection was 13% and is within the range of 1% to 30% as quoted in the literature [8,9]. Although wound complication rates for colorectal surgery have been reported to be as high as 30% [10,11], surgical-site infections in this study occurred in 10% of patients, with an additional 10% having intra-abdominal abscesses. The complications directly caused by IORT were indistinguishable from those caused by the combination of chemotherapy, radiation, and the tumor itself. However, there appeared to be no increase in complications secondary to IORT treatment because rates were similar to those seen in other retrospective series [3–6,12–20]. Although it did not include patients with colon and rectal neoplasms, a previous randomized clinical trial

from the National Cancer Institute also showed no increase in postsurgical complication rates when IORT was used [21,22].

Many of the patients in this study were referred to our center specifically to receive IORT. The tumors in this group of patients were invading local structures on presurgical studies. Any attempt to create a control group of patients from our institution would result in a poorly matched group because all patients with advanced and locally invasive, but probably resectable, disease were considered for IORT. At the time of surgery, the decision to use IORT was made by the attending surgeon and the radiation oncologist.

Several other studies published have been published on use of IORT for colorectal cancers. These studies reported local recurrence rates of 20% to 100% [4,5–7,12–19]. The wide range of results is primarily dependent on the degree of resection achieved at the time of surgery. More complete initial resection resulted in longer survival after surgery. Local control of patients after R0 or R1 resection ranged from 62% to 100% [2,7,14,16–17,20], whereas patients with R2 resections had local control rates between 0% and 75% [2,4,7,12,15,17]. These data correlate with our findings of an overall local control rate of 98%, with our only recurrence occurring in the patient who underwent R2 resection. Although our follow-up is not as long as that seen in some other studies, most of the local recurrences occurred within 24 months. Because our median follow-up was 27 months, we have likely seen many of the local recurrences.

Survival rates in patients receiving IORT at our institution were similar to those reported by other institutions. Three-year survival rates after IORT for colorectal cancers ranged from 20% to 63% for patients with R0 and R1 resections [4,13,17,19]. Survival for the patients with colorectal cancers included in this analysis was 62% at just more than 2 years, which is on the high side of the reported survival range. All of the patients who received IORT for endometrial and ovarian cancers were alive at the conclusion of the study (100% survival).

The IORT method used in this study has several important distinctions from that used in previous studies [23]. Some series have reported the use of high-dose rate brachytherapy and delivery of the radiation through catheters [1,5,24]. Other series used a specially constructed OR within the OR suite dedicated to radiation therapy treatments and delivered electron-beam radiation [2,4,6,18–20] or required the patient be operated on in or transferred to the radiation-therapy department to receive electron-beam radiation [4,12,14–15,17,19]. Such transport is not without risks because it separates the patient from the full range of supplies and personnel available in the OR suite. An OR suite dedicated to radiation therapy decreases the number of ORs available for nonradiation patients. However, by using a mobile radiation therapy unit, radiation can be delivered without reoutfitting the existing ORs and without requiring the patient to be transported during their surgical procedure.

The Mobetron itself differs in several aspects from traditional linear accelerators [23]. It does not have the capacity for photon-beam radiation. However, because the purpose of IORT is delivery of the radiation dose directly to the involved tissue surface, the required 3-cm depth can be

achieved with electron-beam radiation. This machine involves a soft docking system; the cone is attached to the patient rather than to the machine as is true for a standard linear accelerator. There is a relatively low leakage rate for radiation compared with standard linear accelerators because of the low scatter of the electron beam, which allows the radiation to be administered in a typical OR suite without additional shielding. Finally, the Mobetron uses a high dose rate compared with standard linear accelerators. This allows the radiation dose to be given during a much shorter period of time, thus allowing for a shorter surgical procedure.

In summary, IORT in this group of selected patients with locally advanced colorectal malignancies at high risk for failure of local control or the need for exenteration or sacrectomy was associated with excellent outcomes in terms of survival and local recurrence. Acceptable morbidity and mortality rates were achieved. The use of IORT has been shown to be of significant value by this and other studies and should be a tool available to those treating these most challenging of patients.

## References

- [1] Shoup M, Guillem J, Alektiar K, et al. Predictors of survival in recurrent rectal cancer after resection and intraoperative radiotherapy. *Dis Colon Rectum* 2002;45:585–92.
- [2] Kim K, Jessup M, Beard C, et al. Locally advanced rectal carcinoma: pelvic control and morbidity following preoperative radiation therapy, resection, and intraoperative radiation therapy. *Int J Radiat Oncol Biol Phys* 1997;38:777–83.
- [3] Shadahiho S, Suzuki T, Ishikawa K, et al. Preoperative radio/chemoradiotherapy in combination with intraoperative radiotherapy for T3–4Nx rectal cancer. *Eur J Surg Oncol* 2004;30:750–8.
- [4] Gunderson L, Nelson H, Martenson J, et al. Intraoperative electron and external beam irradiation with or without 5-fluorouracil and maximum surgical resection for previously unirradiated, locally recurrent colorectal cancer. *Dis Colon Rectum* 1996;39:1379–95.
- [5] Lowy A, Rich T, Skibber J, et al. Preoperative infusional chemoradiation, selective intraoperative radiation and resection for locally advanced pelvic recurrence of colorectal adenocarcinoma. *Ann Surg* 1996;223:177–85.
- [6] Nag S, Martinez-Monge R, Martin E. Intraoperative electron beam radiotherapy in recurrent colorectal carcinoma. *J Surg Oncol* 1999;72:66–71.
- [7] Willett C, Czito B, Tyler D, et al. Intraoperative electron beam radiation therapy for primary locally advanced rectal and rectosigmoid carcinoma. *J Clin Oncol* 1991;9:843–49.
- [8] Benoist S, Panis Y, Denet C, et al. Optimal duration of urinary drainage after rectal resection: a randomized controlled trial. *Surgery* 1998;125:135–41.
- [9] Marusch F, Gastinger I, Schneider C, et al. Experience as a factor influencing the indications for laparoscopic colorectal surgery and the results. *Surg Endosc* 2001;15:116–20.
- [10] Smith R, Bohl J, McEleavey S, et al. Wound infection after elective colorectal resection. *Ann Surg* 2003;235:599–607.
- [11] Bullard K, Turdel J, Baxter N, et al. Primary perineal wound closure after preoperative radiotherapy and abdominoperineal resection has a high incidence of wound failure. *Dis Colon Rectum* 2005;48:438–43.
- [12] Pezner R, Chu D, Wagman L, et al. Resection with external beam and intraoperative radiotherapy for recurrent colon cancer. *Arch Surg* 1999;134:63–7.
- [13] Suzuki K, Gunderson L, Devine R, et al. Intraoperative irradiation after palliative surgery for locally recurrent rectal cancer. *Cancer* 1995;74:939–52.
- [14] Pezner R, Chu D, Ellenhorn J, et al. Intraoperative radiation therapy for patients with recurrent rectal and sigmoid colon cancer in previously irradiated fields. *Radiother Oncol* 2002;64:47–52.

- [15] Wallace J, Willett C, Shellito P, et al. Intraoperative radiation therapy for locally advanced recurrent rectal or rectosigmoid cancer. *J Surg Oncol* 1995;60:122–7.
- [16] Willett C, Shellito P, Tepper J, et al. Intraoperative electron beam radiation therapy for recurrent locally advanced rectal or rectosigmoid carcinoma. *Cancer* 1991;67:1504–8.
- [17] Nakfoor B, Willett C, Shellito P, et al. The impact of 5-fluorouracil and intraoperative electron beam radiation therapy on the outcome of patients with locally advanced primary rectal and rectosigmoid cancer. *Ann Surg* 1998;228:194–200.
- [18] Haddock M, Gunderson L, Helson H, et al. Intraoperative irradiation for locally recurrent colorectal cancer in previously irradiated patients. *Int J Radiat Oncol Biol Phys* 2001;49:1267–74.
- [19] Gunderson L, Nelson H, Martenson J, et al. Locally advanced primary colorectal cancer: intraoperative electron and external beam irradiation  $\pm$  5-FU. *Int J Radiat Oncol Biol Phys* 1997;37:601–14.
- [20] Roeder F, Treiber M, Oertel S, et al. Patterns of failure and local control after intraoperative electron boost radiotherapy to the presacral space in combination with total mesorectal excision in patients with locally advanced rectal cancer. *Int J Radiat Oncol Biol Phys* 2007;67:1381–8.
- [21] Cromack DT, Maher MM, Hoekstra H, et al. Are complications in intraoperative radiation therapy more frequent than in conventional treatment? *Arch Surg* 1989;124:229–34.
- [22] Sindlar WF, Kinsella TJ. Normal tissue tolerance to intraoperative radiotherapy. *Surg Oncol Clin North Am* 2003;12:925–42.
- [23] Beddar A, Domanovic M, Kubu M. Mobile linear accelerators for intraoperative radiation therapy. *AORN J* 2001;74:700–5.
- [24] Nuytens J, Kolkman-Deurloo I, Vermaas M, et al. High dose-rate intraoperative radiotherapy for close or positive margins in patients with locally advanced or recurrent rectal cancer. *Int J Radiat Oncol Biol Phys* 2004;58:106–12.

( )

( )

( )